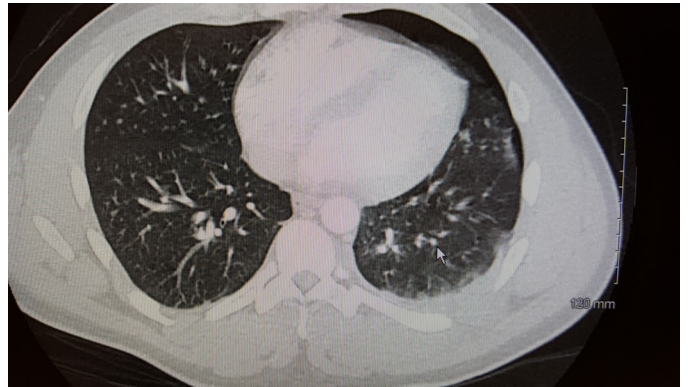
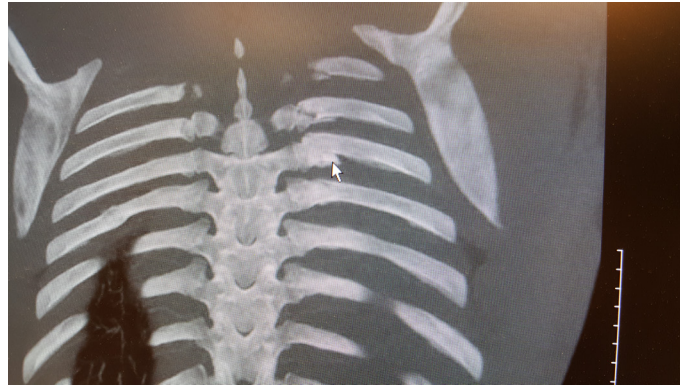
Case Report

A 28 year old male was helmeted motorcyclist on a racetrack. The throttle got stuck and he laid the bike down and was hit in the back by another motorcyclist who couldn't avoid him. He presented to the ED complaining of chest pain. Chest Xray showed a small apical PTX and a displaced left 6th rib fracture. CT of the chest showed left 4-7 rib fractures, and a small hemopneumothorax. He was admitted for pain control, follow up chest Xray. A rib belt was placed on him in the ED. Follow up chest film showed no increase in the small PTX. He was discharged home approximately 36 hours after injury on oral analgesics.

He had a follow up film when he was seen back in the office 10 days after injury. The film showed a very small amount residual pleural fluid, no PTX. He was wearing the rib belt continuously, and he had weaned narcotics to only night-time, otherwise he was taking Tylenol and Motrin.





Case Report Courtesy of:

Lisa A. Patterson, MD, FACS

Concord Hospital

Concord, NH



3419 Westminster #276

Dallas, Texas 75205

1-877-451-3000